Acute Care and Perioperative Point-of-Care Ultrasound

Acute Care and Perioperative Point-of-Care Ultrasound

Edited by

Davinder Ramsingh

Cambridge
Scholars
Publishing

Acute Care and Perioperative Point-of-Care Ultrasound

Edited by Davinder Ramsingh

This book first published 2021

Cambridge Scholars Publishing

Lady Stephenson Library, Newcastle upon Tyne, NE6 2PA, UK

British Library Cataloguing in Publication Data
A catalogue record for this book is available from the British Library

ISBN (10): 1-5275-7123-8
ISBN (13): 978-1-5275-7123-5

F.O.R.E.S.I.G.H.T. Comprehensive Perioperative Ultrasound Examination

Focused
Peri**O**perative
Risk
Evaluation
Sonography
Involving
Gastro-Abdominal
Hemodynamic, and
Trans-Thoracic Ultrasound

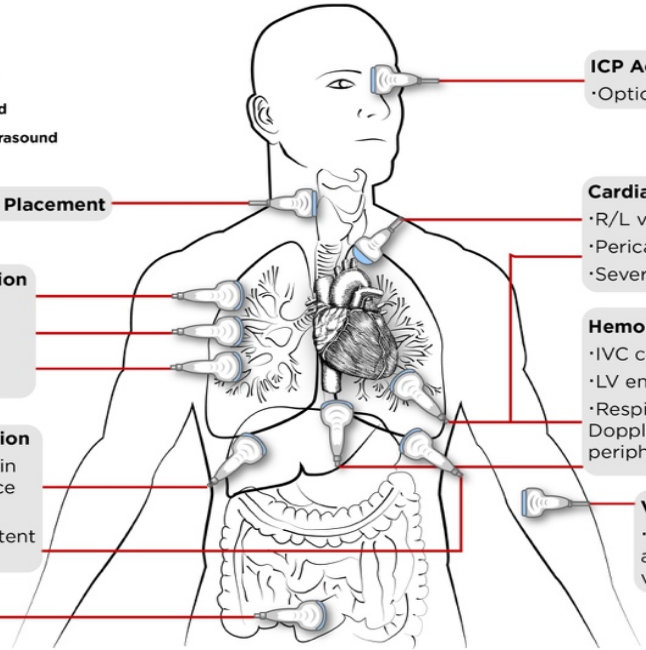

ICP Accessment
- Optic sheath diameter

Endotracheal Tube Placement

Cardiac Evaluation
- R/L ventricular function
- Pericardial effusion
- Severe Valvular abnormalities

Pulmonary Evaluation
- Pneumothroax
- Pleural effusion
- Severe alveolar interstitial disease

Hemodynamics
- IVC collapsibility
- LV end diastolic area
- Respiratory variation on Doppler Flow across LVOT/ peripheral arteries

Abdominal Evaluation
- Evaluate free fluid in interperitoneal space via 3 windows
- Assess gastric content and volume

Vascular Access
- Demonstrate image acquisition of peripheral veins/arteries

TABLE OF CONTENTS

PREFACE

This book is designed to serve as an introduction to the topic of point of care ultrasound and highlight how it can be applied to improve care in acute care and perioperative settings. Each section is designed to be succinct and provide the following: a brief background on the topic, a description/ illustration of image acquisition, and a discussion of essential pathology identification.

Thanks to all of those that have offered their time, advice, expertise, and support for developing this book. Also, many thanks to those that have helped review/edit/design this book, including Drs. Andy Trang, and Ceci Canales. Special thanks to my mentors Drs. Maxime Cannesson, Zeev Kain, Aman Mahajan, and Robert Martin.

Finally, words cannot express my eternal gratitude to my loving wife Sefali, and my wonderful kids Nikhil and Ishani. May life always allow us to endorse the importance of kindness and hard work.

TABLE OF ABBREVIATIONS

ACLS	
AI	Aortic insufficiency
AO	Aortic outflow
AP	Antero-posterior
AS	Aortic stenosis
BMJ	British Medical Journal
CSA	Cross-sectional area
CVP	Central venous pressure
CW	Continuous wave
DVT	Deep vein thrombosis
EF	Ejection fraction
ETT	Endotracheal tube
EVD	External ventricular drains
FAC	Fractional area change
FAST	Focused assessment with sonography for trauma
FS	Fractional shortening
HF	Heart failure
HFpEF	Heart failure with preserved ejection fraction
HFrEF	Heart failure with reduced ejection fraction

ICP	Elevated intracranial pressure
IJ	Internal jugular
IVC	Inferior vena cava
LA	Left atrial
LAX	Long axis
LUQ	Left upper quadrant
LV	Left ventricle
LVEDD	Left ventricle end diastolic diameter
LVEDP	Left ventricle end diastolic pressure
LVOT	Left ventricular outflow tract
MV	Mitral valve
ONSD	Optic nerve sheath diameter
PAP	Pulmonary artery pressure
PE	Pulmonary embolus
PG	Pressure gradients
PICC	Peripherally inserted central catheter
PLAX	Parasternal long axis
PLUS	Pulmonary tree and Lung expansion Ultrasound Study
PMI	Point of maximal impulse
POCUS	Point of care ultrasound
PRF	Pulse repetition frequency
PSAX	Parasternal short axis

PW	Pulse wave
RA	Right arteriole
RAP	Right arteriole pressure
RBC	Red blood cell
RUQ	Right upper quadrant
RV	Right ventricle
RVSP	Right ventricular systolic pressure
SAX	Short axis
SCV	Subclavian vein
SVR	Systemic Vascular Resistance
TDI	Tissue Doppler imaging
TGC	Time gain compensation
TS	Transverse
VTI	Velocity time integral

I

ULTRASOUND PHYSICS

DAVINDER RAMSINGH, MICHAEL MA
AND JARED STAAB



Principles of Ultrasound Physics

Sound Waves

Audible sound waves lie within the range of 20 to 20,000 Hz. Clinical ultrasound systems use transducers that produce sound waves between 2 and 27 MHz. Traditionally, ultrasound waves are produced by passing an electrical current through piezoelectric crystal elements. These elements convert electrical energy into a mechanical ultrasound wave and not only deliver but also can receive ultrasound echoes. Ultrasound images are produced from a collection of emitted and received ultrasound waves. Sound waves are described in terms of **frequency, velocity, wavelength, and amplitude**.

Frequency (*f*): The number of wavelengths per unit of time: 1 cycle / sec = 1 Hz. Frequency is inversely related to wavelength.

Velocity (v): The speed at which waves propagate through a medium (meters per second, m/s).

Wavelength (λ): The distance traveled between two consecutive peaks or troughs of a wave (m).

Amplitude (A): Height of the ultrasound waves, or "loudness" as measured in decibels (dB).

Velocity = Frequency × Wavelength

It is important to note that the velocity of sound waves is dependent on the physical properties of the medium through which they travel. Ultrasound image production relies on the assumption that the velocity within the tissue is a constant, specifically 1540 m/s.

Image Formation

The returning electric signals produced represent "dots" on the screen. The *brightness* of the dots is proportional to the strength of the returning echoes. The location of the dots is determined by travel time. Using the equation below, each returning ultrasound signal is accumulated to produce an image.

Distance = Velocity × Time

Given the constant tissue velocity assumption and preset frequency, the ultrasound machine depicts the location of each reflected ultrasound wave on the display. One can alter the image mostly by adjusting the frequency, which is inversely related to the ultrasound wavelength.

Think of the ultrasound wavelength as a ruler: if one is using a ruler that has only whole inch markings, then measurements will be *less* precise compared to using a ruler with quarter-inch markings. Thus, a longer wavelength provides less detail for an ultrasound image, and a shorter wavelength allows for a more precise or higher quality image.

Along with this principle is the fact that the longer the wavelength, the greater the depth of penetration. This is due to the fact that wavelengths will only penetrate a certain number of cycles to produce an image before they diminish in quantity. This phenomenon is termed attenuation (Figure 1.1).

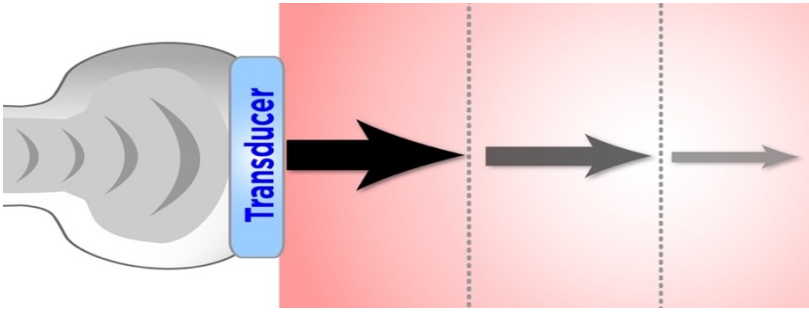

Figure 1.1 Attenuation of ultrasound across tissue planes.
The figure shows the transducer emitting signals across different tissue layers. As the signal penetrates deeper into the tissue, it becomes weaker.

Therefore, an ultrasound probe emitting a longer wavelength (lower frequency) will penetrate the body further and thus produce a better image for deeper structures in comparison to a shorter wavelength probe (Figure 1.2). While this is not a complete explanation, these are the key points to understand:

Figure 1.2 Comparison of liver ultrasound with high frequency probe (12 MHz) vs. low frequency (3 MHz).

- The *HIGHER the frequency, the BETTER the resolution* (shorter wavelength), but this is at the cost of *LESS depth of penetration*.

- The *LOWER the frequency, the WORSE the resolution* (longer wavelength), but *GREATER depth of penetration.*

In effect, lower frequency probes provide better scanning for deeper structures.

Ultrasound Interactions with Tissue

The term attenuation is used to describe what happens to the ultrasound wave as it interacts with the tissue planes. Because of attenuation, the deeper the ultrasound waves travel into the body, the weaker they become. Equally important is to understand that the greater the frequency of the ultrasound wave, the more attenuation occurs at a given depth. Thus, a lower frequency transmission will have less attenuation at a given depth compared to a higher frequency transmission.

Attenuation can be divided into four main processes: reflection, absorption, refraction, and transmission. The additional processes of scattering and diffraction are also demonstrated in Figure 1.3.

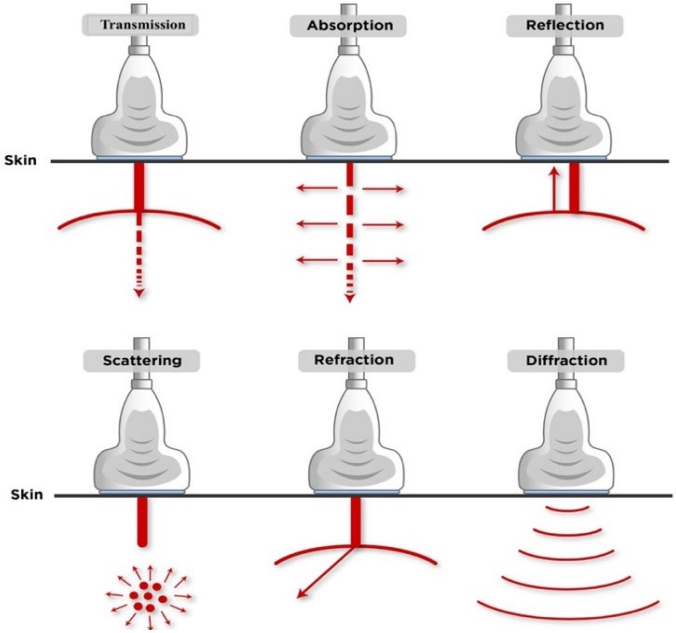

Figure 1.3 Main processes observed in ultrasound.
The six ways an ultrasound probe transmits its signal in the tissue: transmission, absorption, reflection, scattering, refraction, and diffraction. The images show the direction and strength of the ultrasound penetrating into the tissues.

Reflection: This is a mirror-like return of the ultrasound wave to the transducer. Reflections occur at the interface of different densities or acoustic impedances of the tissues. The greater the difference in the density of the tissues, the greater the amount of reflection. This is why one does not see *aerated* lung tissue well with ultrasound—the majority of the ultrasound waves are reflected at the plane between the pleura and the lung. Also, it is important to note that the more perpendicular the structure is to the ultrasound waves, the more hyper-echogenic (or brighter) the image will appear since more ultrasound waves are returned back to the probe. Similarly, the more parallel the structure is to the ultrasound probe, the more hypo-echogenic (dark) the structures will appear since fewer ultrasound waves are reflected back to the probe (Figure 1.4). *Remember, for 2-D images, the ultrasound wave should be as perpendicular as possible to the structure, and for flow assessment, the probe should be as parallel as possible.*

Refraction: This is a change in the direction of the ultrasound wave secondary to a change in the density of one medium to another. This phenomenon creates artifacts in the ultrasound image (Figure 1.4).

Absorption: At each tissue plane, some of the ultrasound waves are absorbed by the tissues and produce heat.

Transmission: This is necessary for one to see various tissues at various depths (Figure 1.5).

It is important to remember that one can counteract the loss of signal during the assessment of deeper structures by altering the power gain/time gain compensation (TGC) variables.

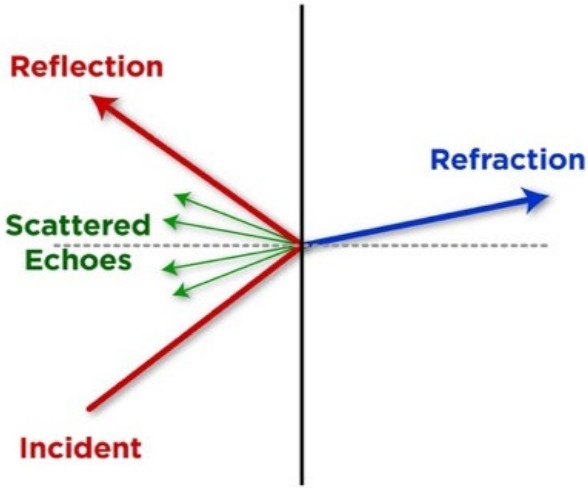

Figure 1.4 Reflection and Refraction.
Reflection occurs when the transducer emits a signal that creates a symmetrical, mirror-like return. Refraction is a result of the signal transmitted from one medium to another. Occasionally artifacts, or scattered echoes, are seen as a result of refraction.

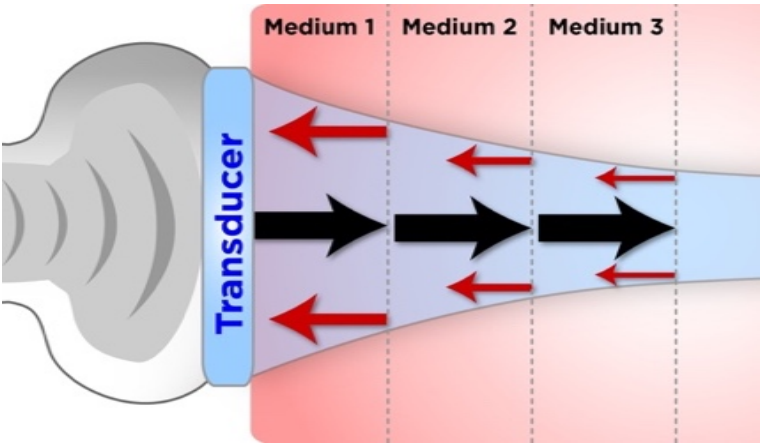

Figure 1.5 Ultrasound Transmission.
The figure demonstrates the loss of ultrasound signal (attenuation) that occurs as it penetrates deeper into tissues.

In addition, it is also important to highlight that ultrasound gel is used between the patient's skin and the transducer footprint. The gel allows a more uniform density between the ultrasound footprint and the patient's skin, which allows for greater transmission.

Transducers

There are three characteristics of transducers that guide probe selection for the desired image acquisition: 1) frequency, 2) insonation footprint, and 3) probe design.

Most often, the choice of the transducer is based on the depth of the structure being imaged, since depth dictates the **frequency** that will be used to insonate. The higher the frequency of the transducer, the less penetration it has; however, the better the resolution. In contrast, the lower the frequency of the transducer crystal, the greater the depth of penetration; however, the resolution will be sacrificed.

The **footprint** is the area of the transducer in which the ultrasound is emitted. This is important since you have to be able to place the probe over the desired area in a manner that allows the ultrasound waves to penetrate the desired tissue. This is particularly relevant when it comes to cardiac

examinations because a small footprint is required to place the probe between the rib spaces since bone is highly ultrasound reflective.

Finally, the **probe design,** or shape of the probe, can vary based on the area where it is designed to be placed on the body.

General Probe Types

There are three main probes utilized in point of care ultrasound: low frequency phased array (cardiac), low frequency curved linear (abdominal), and high frequency linear.

Phased Array:

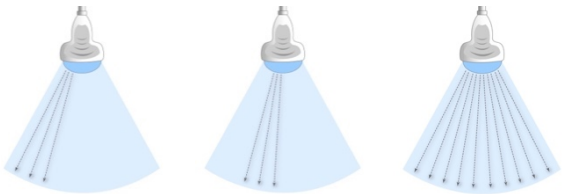

This probe allows for a significantly larger width of image acquisition compared with the footprint. This is achieved by sending directional "phases" of ultrasound wavelengths that are rapidly pulsated and composited together to produce an image. How rapidly the phases are emitted is related to the *frame rate.*

Curved Linear:

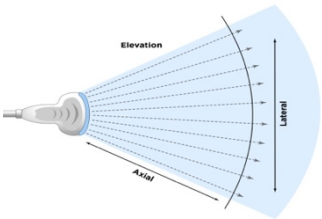

This probe has an emitting frequency of 4 to 7 MHz and a large footprint, ideal for abdominal examinations. A wide image is produced because of how the ultrasound waves are emitted (curved).

Linear:

This probe has an emitting frequency of 10 to 27 MHz, is used for superficial structures, and provides the best image resolution.

Resolution

Image resolution is defined as the ability to distinguish two points in space. It consists of two components: spatial and temporal resolution.

Spatial resolution is the smallest distance between two points that allows a system to identify them as two separate targets or the ability to distinguish two separate points in space (Figure 1.6). Spatial resolution consists of two parts—*axial and lateral. Axial resolution* is the minimum separation between structures that are parallel to the ultrasound beam path. Axial resolution is directly related to frequency, pulse length (period of wavelengths), and inversely related to wavelength. *Lateral resolution* is the minimum separation between structures that are perpendicular to the ultrasound beam's path. Lateral resolution is modified by the ultrasound wave amplitude, the image depth, and the gain intensity.

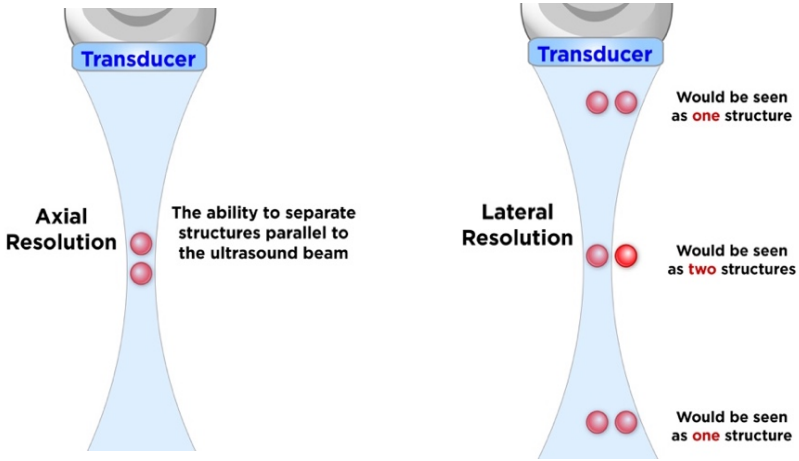

Figure 1.6 Axial vs lateral components of spatial resolution.

Temporal resolution is the ability of a system to accurately track moving targets over time. Any factor that increases time requirements will decrease temporal resolution. Such factors include 1) depth, 2) sweep angle, 3) line density, and 4) lower frequency or pulse repetition frequency (PRF).

Commonly Used Methods of Improving Ultrasound Images

Depth: Represents the number of pixels per centimeter and directly affects the spatial resolution. One should always adjust the depth to the minimum appropriate level in which all relevant structures are visualized. This will result in the highest frequency and thus an improved image resolution.

Gain: Adjusts the overall brightness of the ultrasound image. It is important to note that this is a post-processing adjustment, therefore increasing gain does not improve the differentiation of echogenicity, i.e., the resolution is the same just brighter or darker (you can adjust the power to improve the image differentiation of echogenicity).

Power: Relates to the strength of the voltage spike applied to the crystal for each pulse. Increasing the power output increases the intensity of the beam and, as a result, the strength of the echo that is returned to the transducer.

Focus: Indicates the focal zone of each transducer where the best image resolution can be achieved. This is indicated on the ultrasound system with a small triangle or line to the right of the image. Effort should be taken to position the object of interest within the focal zone to obtain the clearest image.

Time Gain Compensation (TGC): This helps equalize the differences in received reflection amplitudes as the signal is diminished over the reflector depth. TGC allows for adjustment of the amplitude to compensate for the path length differences (it counteracts the fact that fewer wavelengths penetrate to deeper structures resulting in a less echogenic image). You can think of TGC as bands of "horizontal gain."

Ultrasound Modes

B-Mode (Brightness Mode):

This is the mode used for standard 2-D image creation and real-time scanning. Different levels of gray are shown based on the amplitude of the received ultrasound signals. Typically, the brighter shades represent greater degrees of ultrasound reflection. Since 2-D images are generated from reflection, the best 2-D or B images occur when the ultrasound plane is perpendicular to the structure.

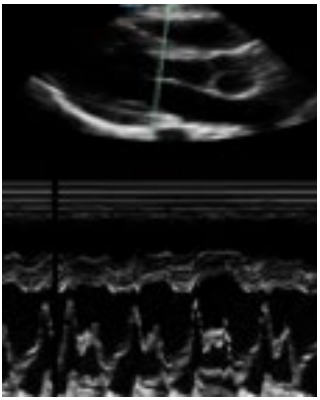

Figure 1.7 M-Mode (Motion Mode)

M-Mode (Motion Mode): This is a graphic B-mode pattern that is a single line time display that represents the motion of structures along the ultrasound beam at 1000 fps. In this mode, the lines of ultrasound reflections or returning echoes are shown in the y-axis, and their changes over time are shown in the x-axis (Figure 1.7). This mode allows you to trace motion (i.e., heart wall motion and vessel wall motion).

Doppler:

This modality displays the change in frequency of a wave resulting from the motion of the source producing the ultrasound reflection (Figure 1.8). The detected change in frequency is termed the Doppler shift. This shift in reflection can be displayed graphically and is audible. In point of care ultrasound, the reflector is often moving blood, but it can also be various other tissues as well.

If the blood is moving away from the transducer, a lower frequency is detected (negative shift), and the spectrum appears below the baseline. Conversely, if the blood is moving toward the transducer, a higher frequency (positive shift) is detected, and the display is shown above the baseline. The amplitude of the signal is proportional to the magnitude of the motion signal (most often blood), indicated by various shades of gray.

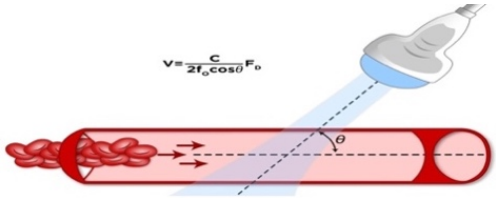

Figure 1.8 Doppler Principle

It is crucial to minimize the angle of the Doppler probe from the direction of flow to be able to assess the direction and velocity appropriately.

The Doppler shift is dependent on the insonating frequency (transducer frequency), the velocity of the moving red blood cells, the angle of the ultrasound beam, and the direction of the moving structure of interest. (Figure 1.8). Ideally, the angle of the ultrasound beam (transducer) should be less than 60 degrees to the pathway of flow being assessed to obtain an accurate and quantifiable evaluation of the motion. It is important to realize that *if the sound beam is perpendicular to the direction of blood flow, there will be no Doppler shift*, and consequently, no display of flow. Thus, optimization of Doppler assessment involves aligning the ultrasound probe plane to be as near to parallel to the flow as possible. If the item being assessed via Doppler (often blood) is moving away from the transducer, a lower frequency is detected (negative shift), and the spectrum appears below the baseline. Conversely, if the item being assessed is moving toward the transducer, a higher frequency (positive shift) is detected, and the display is shown above the baseline. The amplitude of the Doppler signal is proportional to the density of the entity be assessed (most often blood), which is represented by various shades of gray.

There are three main types of Doppler Ultrasound: 1. Pulse-Wave, 2. Continuous Wave, 3. Color Doppler.

Pulse Wave (PW) Doppler:

Pulse wave Doppler is a modality that provides an audible and visual display of motion at a *specific location*. Thus, PW offers the benefit of providing depth discrimination of where the Doppler signal is originating (Figure 1.9). However, because PW involves identifying a velocity sample in a particular location, the transit time required to reach that location must be factored in and produces a limitation on the range

of velocity values that can be assessed. The spread of this range decreases the further the sample location is from the probe. In summary, PW is useful to assess the velocity at a specific location; however, it is limited by the range of velocities that it can assess.

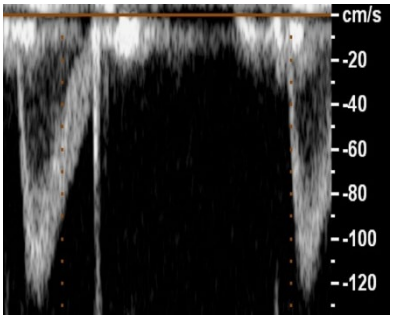

Figure 1.9 Pulse Wave Doppler

PW allows the localization of Doppler signal with a limitation on the range of velocities that can be displayed.

Continuous Wave (CW) Doppler:

CW allows assessment of all the velocities along a Doppler beam path, there is no ability to localize where the velocities originate in this path.

In this modality, ultrasound is constantly sending and receiving Doppler signals along the identified path of insonation (Figure 1.10). The benefit of this modality over PW Doppler is that there is no limitation on the range of velocities that can be assessed. However, the trade-off is the loss of depth localization. In other words, a CW Doppler will show a summation of *all* the velocities along the Doppler beam path (Figure 1.11).

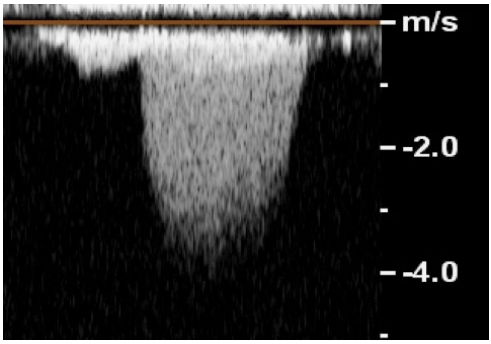

Figure 1.10 Continuous Wave Doppler

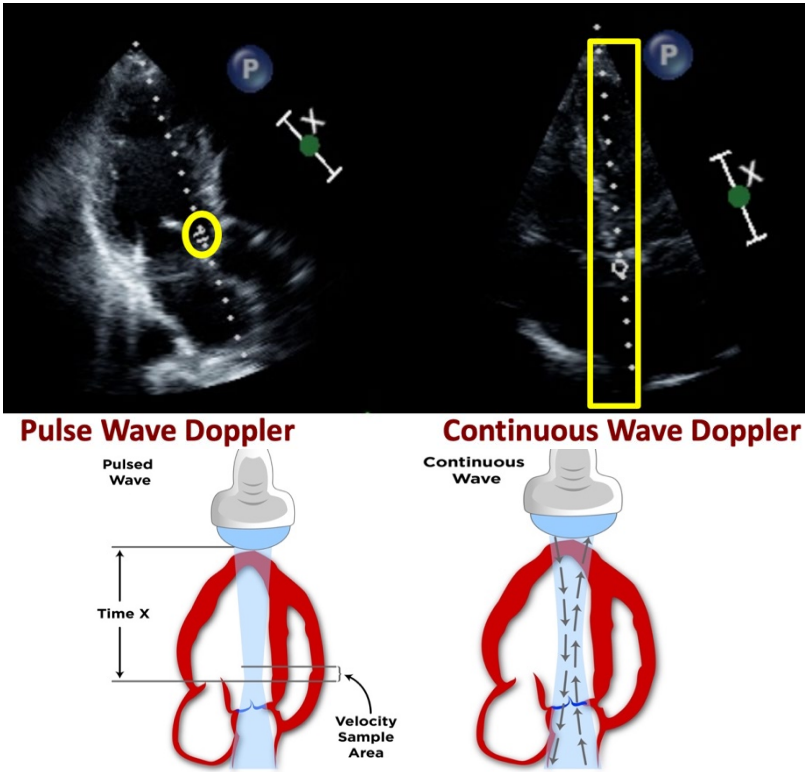

Figure 1.11 Doppler Zones for Pulse Wave and Continuous Wave Doppler